
Just Right- Our Experience with the Goldilocks Mastectomy

Anna Sandstrom*, David Lim and Vanitha Budhavaram

Royal Perth Hospital, Perth, Australia

*Corresponding author: Anna Sandstrom, Royal Perth Hospital, Perth, Australia. E-mail: anna.lou.sandstrom@gmail.com

Received: November 26, 2025; **Accepted:** December 12, 2025; **Published:** January 05, 2026

Abstract

Background: The Goldilocks mastectomy was first described in 2012 as an alternative option for those patients who may not be suitable for implant or autologous reconstruction due to obesity, advanced age, smoking history and ptosis. The principles are to perform a skin reducing mastectomy through a Wise pattern incision with preservation of the de-epithelialised inferior lipodermal flap which is then folded to create a breast mound. It is a single step procedure with a shorter operative time and lower complication rate. There have been relatively few studies in the literature reviewing application and outcomes.

Case Description: We performed 4 Goldilocks mastectomies over a 12 month period, with the indications including obesity, significant ptosis and patient preference. Favourable cosmetic outcomes were observed with a low complication rate, noting only with only minor wound problems.

Conclusion: This case study adds to the literature by demonstrating that the Goldilocks mastectomy is a safe and cosmetically pleasing option to consider in patients who prefer a breast reconstruction but may not be suitable for the more traditional methods. We also extended its use to a younger patient as a staged procedure in a patient who is not currently suitable for a deep inferior perforator flap (DIEP) reconstruction due to her weight.

Introduction

Breast cancer is the 2nd most common cancer in Australia with 1 in 7 women being diagnosed in their lifetime. Twenty-eight percent of breast cancer patient are obese and, unfortunately, these patients can experience a 2.3 times higher rate of complication with a 1.9 times higher risk of a reoperation [1]. This can present challenges and limitations when considering breast reconstruction and can preclude them from these options.

The Goldilocks mastectomy was introduced in 2012 as an alternative technique to breast reconstruction in those patients who are not suitable for conventional methods of reconstruction. Particularly, this can include patients with obesity, advanced age, ptosis and smoking history. It was first described by Richardson and Ma as a form of autologous reconstruction using the deepithelialised inferior mastectomy flap to recreate a breast mound. It has the advantage of being a single step procedure with a shorter operative time, while avoiding the complications of an implant or free flap.

Despite this technique being introduced more than a decade ago, few studies have published application of this technique and outcomes. A cohort study by Alhussini et al followed 55 patients for a median of 36 months who underwent a Goldilocks mastectomy [2]. The median BMI was 41.2 with 98.2% of patients self-reporting to be satisfied or extremely satisfied. Oliver et al reported 172 operations at their institution and demonstrated safety, efficacy and satisfactory aesthetic outcomes and advocated for its use in higher risk patients [3].

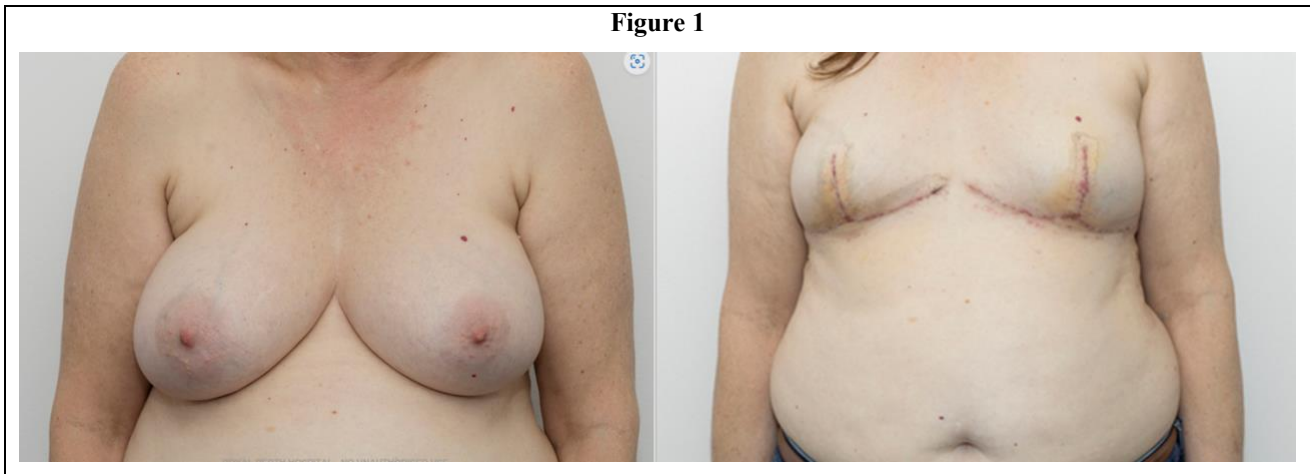Other modifications to the Goldilocks mastectomy reported in the literature include grafting the nipple, sparing the nipple, providing a bridge to a secondary reconstructive procedure and augmenting volume using perforator flaps. In a case report by Ter Louw et al the nipple was excised, thinned to the dermal level and placed as a graft on deepithelialised tissue [4]. Richardson et al described a nipple sparing Goldilocks where a broad based nipple areolar pedicle is utilised to preserve the small perforator vessels entering medially [5]. The Goldilocks mastectomy has also been modified to be performed as a nipple sparing mastectomy with immediate pre-pectoral implant based reconstruction with Bovill et al reporting a case of a patient with ptotic breasts and multifocal cancer where the nipple areolar complex on the lipodermal flap formed the inferior sling and anterior coverage of the implant [6]. Schwarz et al noted that one of the criticisms of the Goldilocks was the lack of residual volume and so they included 14 patients who had a Goldilocks mastectomy combined with a lateral intercostal artery perforator flap and a free nipple graft [7]. The inferior mastectomy flap was deepithelialised in continuity with the LICAP flap. The LICAP flap was then mobilised to its pivot point and translated as far medially as possible with the inferior mastectomy flap wrapped around the LICAP flap to increase volume.

In our tertiary institution, where we perform and have access to implant and flap based autologous reconstructions, we have performed four Goldilocks mastectomies over a twelve month period. Our technique involves marking a Wise pattern preoperatively, using the point of the inframammary fold as the apex with a medial and lateral limb length of 10-12cm. Intraoperatively, the inferior lipodermal flap is de-epithelialized along the entire width, creating a broad flap then nipple excising skin sparing mastectomy is performed in the mastectomy plane. The lipodermal flap is then rolled in on itself and secured to the chest wall with PDS sutures to create a breast mound. The flap can also be split vertically and overlapped to create additional volume if required. Sentinel node can be performed though the same incision if required, followed by a pectoralis block with a drain left in situ. The wounds are then closed in a standard inverted T fashion.

Case Presentation

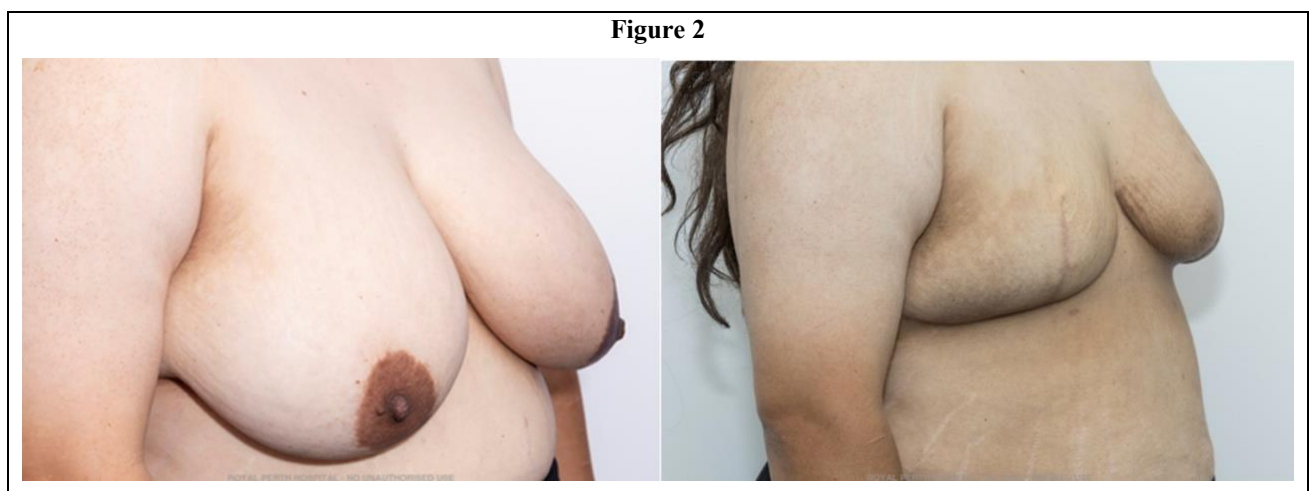
Case 1

Patient 1 is a 54 year old female with screen detected calcifications of the right breast, defined to be 80 x 90mm on contrast enhanced mammogram. A core biopsy revealed an estrogen positive grade 1 invasive ductal carcinoma. There was also a 5mm lesion on the contralateral breast but, unfortunately, due to severe needle phobia, attempts to biopsy this were unsuccessful. She had a background of asthma, GORD and dyslipidaemia and was a non-smoker with a BMI of 26 with D cup breasts. Avoiding repeated procedures or further biopsies was a priority for her and her preference was to avoid implant or a deep inferior epigastric perforator (DIEP) reconstruction so a bilateral nipple sacrificing Goldilocks procedure with sentinel node biopsy was performed (Figure 1). There were no post operative complications.



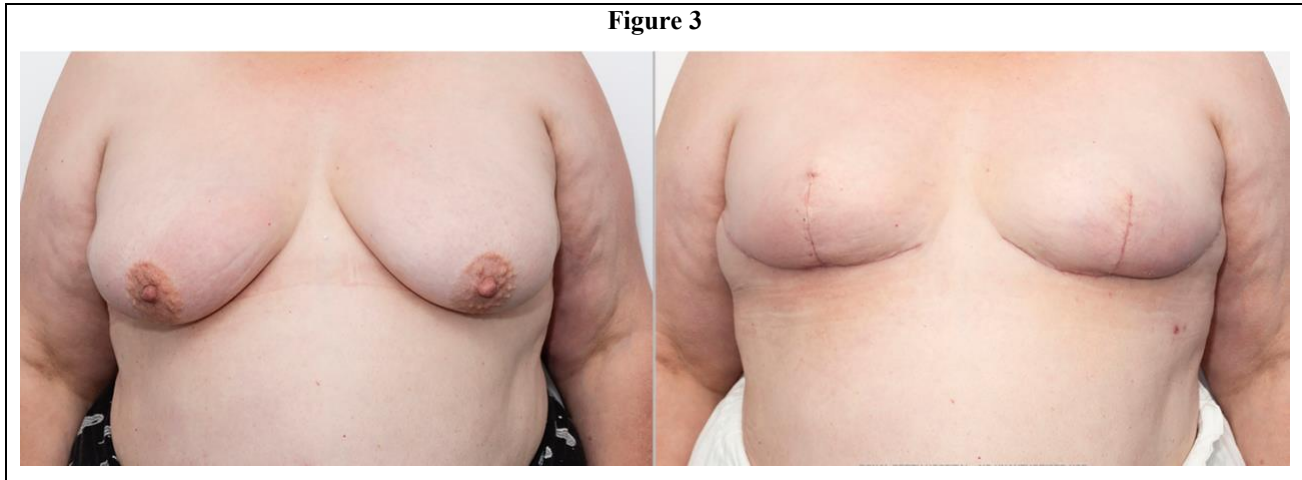
Case 2

Patient 3 is a 34 year old female with a self-detected left breast mass. Imaging demonstrated a 20mm lesion of the left breast and core biopsy confirming a grade 1 invasive ductal carcinoma ER+/PR+/Her2-. She initially had a left breast wide local excision and sentinel node biopsy that showed a 40mm grade 1 invasive ductal cancer ER+/PR+/Her2- with involved margins and 2/3 nodes positive. An axillary lymph node clearance and a re-excision of margins was then performed which unfortunately showed residual cancer and DCIS with close margins and 14/21 nodes positive. She completed her adjuvant chemotherapy and then had further re-excision but clear margins were still not attained so mastectomy was planned. Her preference was for a DIEP reconstruction; however, her BMI was 39, precluding her from this option (Figure 2). Bilateral nipple sacrificing Goldilocks mastectomy were performed with a view to considering delayed DIEP reconstruction with future weight loss. There was some bruising post operatively but no significant complications. She did require adjuvant radiotherapy treatment and this has caused some asymmetry between the breasts and, an alternate option, if desired BMI not reached, is to perform lipofilling of the left breast.



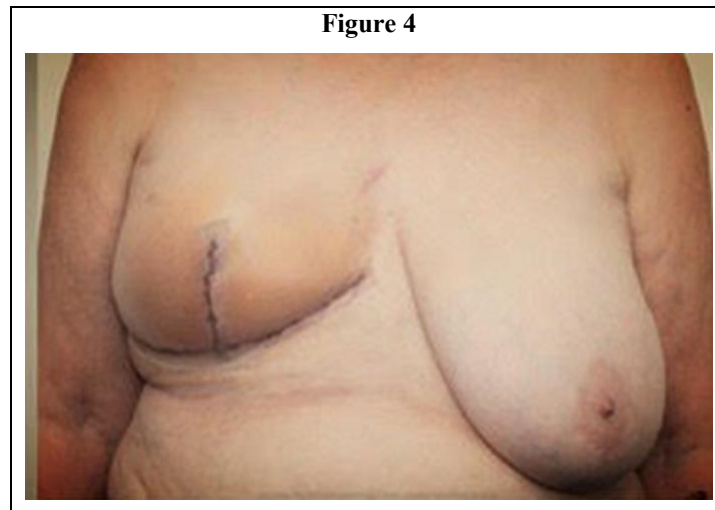
Case 3

Patient 3 is a 60 year old female with a self-detected right breast cancer and nodal involvement. She initially underwent a wide local excision and axillary lymph node clearance that revealed a 35mm grade 3 invasive ductal carcinoma ER+/PR+/Her2- with 1/25 nodes positive. She had adjuvant chemotherapy and, during this time, was found to be BRCA 1 positive on genetic testing. Her BMI was 43 and so, when discussing risk reducing mastectomies, neither DIEP or implant reconstruction were suitable and so bilateral nipple sacrificing Goldilocks mastectomies were performed (Figure 3.). Post operatively, there was some mild cellulitis of the left breast that settled with oral antibiotics.



Case 4

Patient 4 is a 69 year old female with screen detected 20mm high grade DCIS of the right breast. Her background was pertinent for right breast DCIS in 2010 managed with a wide local excision and adjuvant radiation and so required a mastectomy for treatment of her current DCIS. She did not have any significant medical comorbidities but she had grade 3 ptosis of her breasts. She preferred a reconstructive option and so a right nipple excising Goldilocks mastectomy was performed (Figure 4). A course of oral antibiotics was prescribed post operatively for some mild cellulitis but no further complications experienced. She is currently waiting for a left sided symmetrising surgery.



Discussion

In our institution, we have performed 4 Goldilocks mastectomies over a 12 month period, with the most common reasons being ineligibility or personal preference to avoid implant or flap based autologous reconstructions. There were no significant post operative complications with the only issues being minor bruising and mild cellulitis requiring oral antibiotics. To date, we have only performed nipple sacrificing procedures and the next step will be to expand our technique to include nipple preserving Goldilocks mastectomy in the appropriate patient.

The Goldilocks is a versatile procedure with a short learning curve that can be performed in patients who are not suitable candidates for more complex forms of reconstruction due to age, comorbidities or obesity. It is also a viable option for those who wish to avoid these procedures but would like some form of reconstruction. Additionally, in younger patients, it can be used as the first stage toward an autologous reconstruction in the future if weight loss is attained. Furthermore, it has the potential to be performed in more rural and regional areas where access to reconstruction is limited.

Conclusion

The Goldilocks mastectomy is an alternative method of breast reconstruction to be considered in patients desiring some form of reconstruction in whom other forms of reconstruction are contraindicated.

REFERENCES

1. Nahabet EH, Crisera CA. The challenging patient in autologous breast reconstruction: Obesity, breast ptosis and beyond. *Gland Surg.* 2023; 12: 1290-1304.
2. Alhussini MA, Mohamed SM, Elfayoumi T, et al. Goldilocks mastectomy: A modified technique enhancing the aesthetic outcome presented as a single center single-arm prospective cohort study. *Eur J Surg Oncol.* 2024; 50: 108586.
3. Oliver JD, Chaudhry A, Vyas KS, et al. Aesthetic Goldilocks mastectomy and breast reconstruction: Promoting its use in the ideal candidate. *Gland Surg.* 2018; 7: 493-495.
4. Ter Louw RP, Bruce SB, Nahabedian MY. Partial breast reconstruction with Goldilocks technique after excision of giant fibroadenoma: A case report. *Plast Reconstr Surg Glob Open.* 2017; 5: 200.
5. Richardson H, Aronowitz JA. Goldilocks mastectomy with bilateral in situ nipple preservation via dermal pedicle. *Plast Reconstr Surg Glob Open.* 2018; 6: 748.
6. Bovill JD, Deldar R, Wang J, et al. Modified Goldilocks nipple-sparing mastectomy with immediate prepectoral implant-based reconstruction: A case report. *Gland Surg.* 2022; 11: 927-931.
7. Schwartz JD. Toward a more definitive Goldilocks mastectomy: Simultaneous addition of the lateral intercostal perforator flap. *Plast Reconstr Surg Glob Open.* 2019; 7: 132.